

## Soft Tissue Calcifications Under Bisphosphonates-A Causal Relationship?

Marc Schmalzing\* and Hans-Peter Tony

Department of Internal Medicine II, University Hospital Würzburg, Germany

\*Corresponding author: Marc Schmalzing, MD, Rheumatology / Immunology, Centre for Internal Medicine, University Hospital Würzburg, Oberdürrbacher Str. 6, 97080 Würzburg, Germany, Fax: +49931 201 640100; Tel: +49931 201 40100; E-mail: [Schmalzing\\_m@ukw.de](mailto:Schmalzing_m@ukw.de)

Received date: July 24, 2014, Accepted date: August 22, 2014, Published date: August 29, 2014

Copyright: © 2014 Schmalzing M, et al. This is an open-access article distributed under the terms of the Creative Commons Attribution License, which permits unrestricted use, distribution, and reproduction in any medium, provided the original author and source are credited.

### Abstract

The patient, a 75-year-old woman with rheumatoid arthritis presented with a 3-months history of severe pain of both upper arms which could be triggered by pressure. On physical examination palpation of her dorsal upper arms revealed multiple hard mobile subcutaneous nodules with marked tenderness. These could be confirmed on X-ray of her right upper arm in two plains, where multiple calcified subcutaneous nodules could be documented. At first a rare side effect of zoledronic acid which the patient received for osteoporosis was suspected. After thorough questioning the patient remembered, that she had received a 24-hour monitoring of her blood pressure shortly before the onset of her chief complaint, during which the blood pressure cuff had caused her severe pain. Based on the morphology of the calcifications and the patient's history the diagnosis of dystrophic soft tissue calcifications secondary to trauma by blood pressure cuff was established.

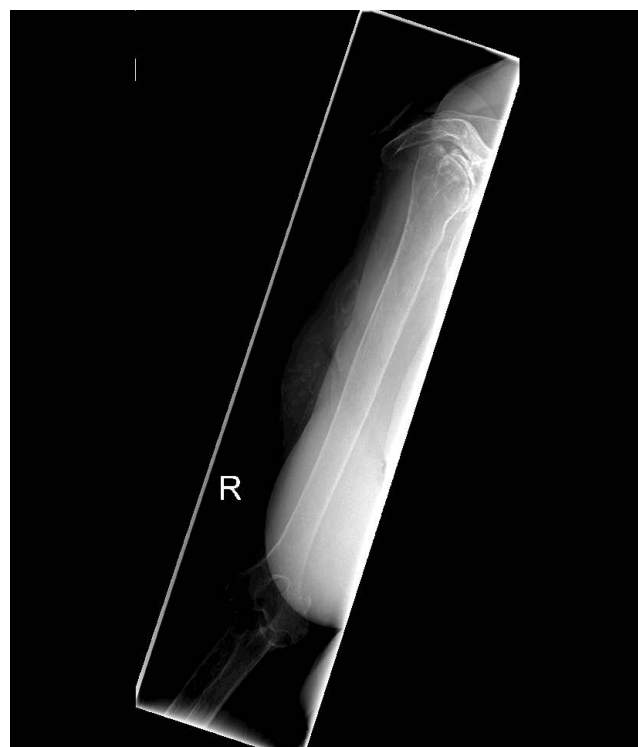
In conclusion, a patient is presented who developed dystrophic subcutaneous calcifications secondary to light trauma after one infusion of zoledronic acid several months ago. The role of zoledronic acid as contributing factor was probably small or non-existent, since cutaneous calcification has been described as a side effect of bisphosphonates only once in the literature, and under a much higher dose.

### Case Report

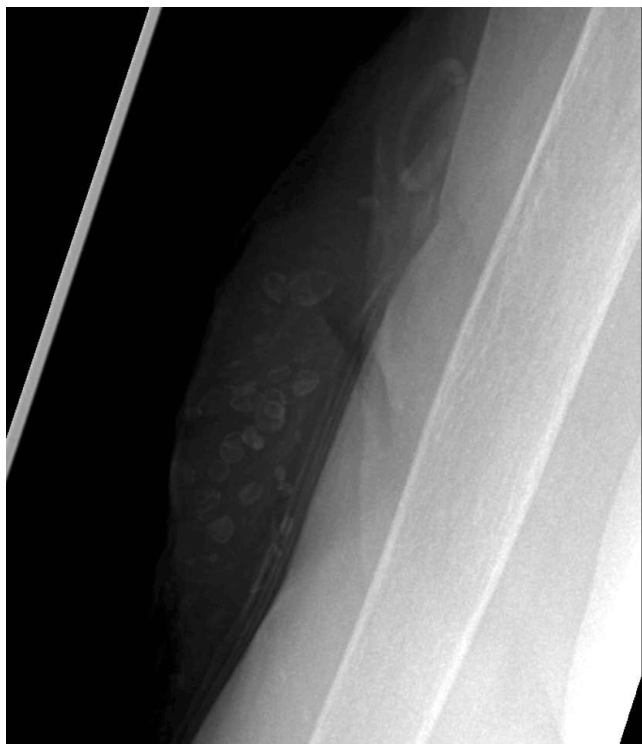The patient, a 75-year-old woman suffered from rheumatoid arthritis for 32 years. She has received numerous disease-modifying drugs und biologics in the course of her debilitating disease. Her current medication for her rheumatic disease was rituximab and low dose prednisolone. She showed advanced chronic destruction of almost all peripheral joints, and developed severe osteoporosis mainly due to a high cumulative dose of corticosteroids. For osteoporosis she had received one single infusion of zoledronic acid 7 months before presentation, but she did not take vitamin D due to an irrational fear of side effects.

She presented with a 3-months history of severe pain of both upper arms which could be triggered by pressure. On physical examination palpation of her dorsal upper arms revealed multiple hard mobile subcutaneous nodules with marked tenderness. These could be confirmed on X-ray of her right upper arm in two plains, where multiple calcified subcutaneous nodules of different sizes ranging from 1 to 11 mm in diameter could be documented (Figures 1 and 2). Laboratory tests revealed a reduced 25-OH-Vitamin D of 15.8 µg/l, but serum calcium, phosphate und parathormone were within normal range.

At first, a rare side effect of zoledronic acid was suspected. However, to our knowledge there is only one case report in the literature describing a cutaneous calcification under bisphosphonate therapy (zoledronic acid for 5 years and clodronate for 2 years) for breast cancer [1]. Therefore, in contrast to our patient, this patient received a much higher dose of bisphosphonates.



**Figure 1:** X-ray of subcutaneous soft tissue calcifications of the right upper arm.



**Figure 2:** Enlarged detail of Figure 1.

After thorough questioning the patient remembered, that she had received a 24-hour monitoring of her blood pressure shortly before the onset of her chief complaint, during which the blood pressure cuff—which was changed from one arm to the other in the course of the examination—had caused her severe pain. Based on the morphology of the calcifications, the localization of both “traumatized” upper arms,

and the patient’s history the diagnosis of dystrophic soft tissue calcifications secondary to trauma by blood pressure cuff was established. Bisphosphonate therapy as another possible etiology seemed rather unlikely, since adverse cutaneous events with bisphosphonates are very rare. Nevertheless, the single infusion of zoledronic acid could have been a contributing factor for calcifications secondary to trauma. Furthermore it has to be stated that the patient was exposed to a high cumulative dosage of corticosteroids causing generalized atrophy of her skin and vasculopathy of her subcutaneous blood vessels leading to a higher probability of dystrophic changes after subcutaneous injury, even if a trauma was trivial. Other drugs which the patient was taking are not known to cause calcifications whatsoever.

Surgical removal of these calcifications was refused by the patient, as were further measurements of her blood pressure.

In general, dystrophic calcification occurs secondary to transient or persisting local tissue injury, while calcium and phosphate metabolism is normal almost without exception. Changes of the connective tissue can make the patient more prone to calcification. Most cases of dystrophic calcification described in the literature are associated with leg ulcers due to chronic venous disease. Other associated conditions include connective tissue diseases, panniculitis, porphyria cutanea tarda, pseudoxanthoma elasticum, cutaneous malignancies, and Ehler-Danlos syndrome. All these are known to cause inflammation or greater vulnerability of the subcutaneous tissue.

In conclusion, a patient is presented who developed dystrophic subcutaneous calcifications secondary to light trauma after one infusion of zoledronic acid several months ago. The role of zoledronic acid as contributing factor was probably small or non-existent.

## References

1. Tatli AM, Gunduz S, Göksu SS, Arslan D, Uysal M, et al. (2013) Dystrophic Cutaneous Calcification and Metaplastic Bone Formation due to Long Term Bisphosphonate Use in Breast Cancer. Case Rep Oncol Med 2013: 871917.