

Case Report

Open Access

Rectus Femoris and Sartorius Muscle Flap for Graft Infection in the Groin

Thomas Lesser *

Department of Thoracic and Vascular Surgery, SRH Wald-Klinikum Gera, Teaching Hospital of the University Hospital Jena, Germany

Keywords: Vascular grafts; Aortobifemoral; Profunda femoris artery

Introduction

Infections of vascular prosthesis are severe adverse events following vascular reconstruction. The incidence varying between 1 and 6 per cent, depending on the anatomical site, with the highest rate occurring in vascular access grafts placed in inguinal and lower extremity incisions in patients undergoing bypass procedures [1,2]. The management of infected prosthetic vascular grafts continues to be controversial. Mostly graft infections were treated by removal with extra-anatomic bypass. In appropriate cases, a graft salvage can be tried. According to the classification by Zühlke and Harnoss explantation of the graft in cases of prosthesis infection without involving the anastomosis is not absolutely necessary [3].

Case Presentation

An 81-year-old man with previous pelvic radiation for a urinary bladder tumor and two prior jejunum resections for intestinal obstruction underwent axillobifemoral extra-anatomic bypass for chronic Leriche's syndrome. Eight months later, the bypass graft was removed because of infection, and an aortobifemoral bypass graft (silver) was inserted via a left-retroperitoneal approach. After 1.5 years, the patient developed a fever and left groin abscess, and a computed tomography (CT) scan demonstrated fluid and air surrounding the left limb of the aortobifemoral graft (Figure 1).

The patient was brought to the operating room and the left limb of the aortobifemoral graft was exposed. The inguinal anastomosis was well-incorporated and there was no evidence of acute inflammation. Periprosthetic fluid was detected above the inguinal anastomosis up to the psoas muscle. No fluid was evident at the graft bifurcation. Extensive surgical debridement of the graft surrounding tissue was performed and vacuum therapy was applied for 2 weeks to the surgical wound. Microbiological examinations were negative. However, 12 cm of the graft remained exposed (Figure 2). A rectus femoris and sartorius muscle flap was used to cover the exposed graft. The rectus femoris was dissected from the vastus medialis and lateralis muscles and divided distally. The muscle fascia was removed. The muscles pedicled on the branches of the profunda femoris artery were folded to cover the prosthesis circularly up to the pelvis (Figure 3). Five days later the muscle was covered with a meshgraft. Oral antibiotic therapy with amoxicillin/clavulanic acid 875 mg/125 mg twice a day was initiated postoperatively for 6 weeks. The groin healed primarily and there was no evidence of recurrent infection.

Figure 4 shows the patient's groin after 6 months. Follow-up CT demonstrated no fluid surrounding the graft (Figure 5).

Discussion

Infected grafts in the groin can lead to severe problems including amputation and death. There are no established treatment options for this complication. Current treatments for prosthetic vascular graft infection include attempted graft preservation, graft removal with in situ graft replacement, and graft removal with extra-anatomic bypass. Morbidity and mortality associated with treatment and likelihood of

persistent or recurrent infection vary among these types of treatment [1]. Graft infections involving the inguinal anastomosis require extra-anatomic reconstruction to the popliteal level. When the anastomosis is well-incorporated and not infected, the graft may be left *in situ*; however, covering the graft with well vascularized tissue is important. Rotational muscle flap coverage is effective in treating locally-infected vascular bypass grafts [4,5]. A rectus femoris muscle flap is a good option if the wound surface is large and the sartorius muscle alone is not enough, as it allows graft coverage far cranially into the iliac region.

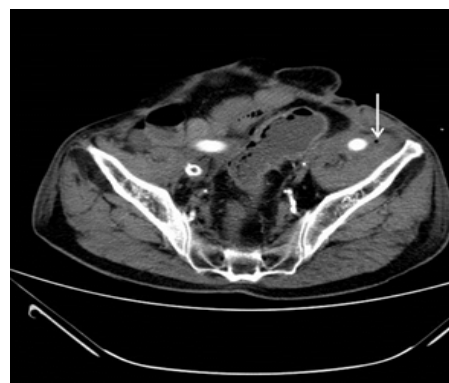


Figure 1: Computed tomography scan demonstrated fluid and air surrounding the left limb of the aortobifemoral graft (arrow).

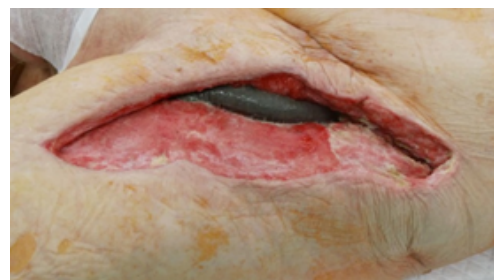


Figure 2: Left groin wound after vacuum therapy for 2 weeks with the exposed graft.

***Corresponding author:** Thomas Lesser, MD, Department of thoracic and vascular surgery, SRH Wald-Klinikum Gera, Teaching Hospital of the University Hospital of Jena, Straße des, Friedens 122, D-07548 Gera, Tel: 0049-3658283151; Fax: 0049-3658283159; E-mail: Thomas.lesser@wkg.srh.de, Thomas.lesser@versanetonline.de

Received May 28, 2015; Accepted June 25, 2015; Published June 27, 2015

Citation: Lesser T (2015) Rectus Femoris and Sartorius Muscle Flap for Graft Infection in the Groin. J Vasc Med Surg S1: 005. doi:10.4172/2329-6925.S1-005

Copyright: © 2015 Lesser T. This is an open-access article distributed under the terms of the Creative Commons Attribution License, which permits unrestricted use, distribution, and reproduction in any medium, provided the original author and source are credited.

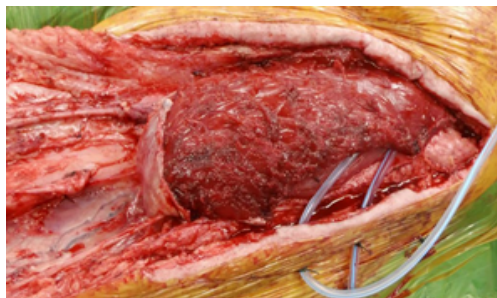

Figure 3: Covering the prosthesis circularly with sartorius and rectus femoris muscles flaps that was folded up.

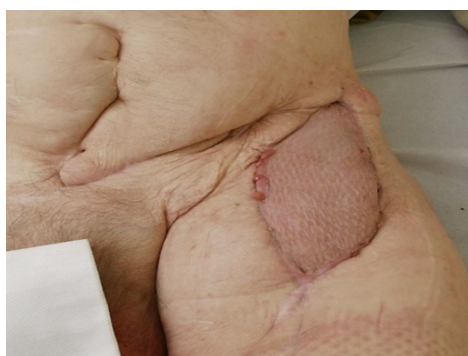

Figure 4: Healed groin by well-incorporated muscle flap without signs of infection.

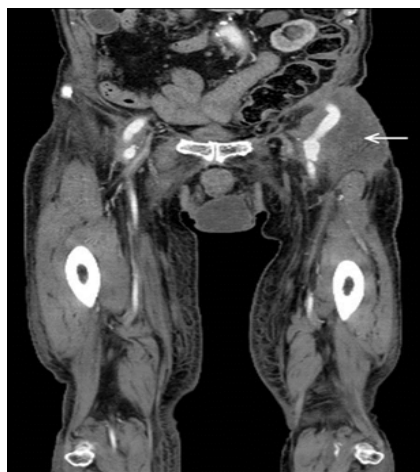

Figure 5: Follow-up CT demonstrated no fluid surrounding the graft (arrow: muscle flap).

In the absence of retroperitoneal spreading of the infection, the rectus femoris muscle flap based on proximal insertion mobilization is a less invasive alternative to cover infected vascular grafts in the groin [6].

To achieve decontamination and infection control, various options such as open wound treatment, or vacuum therapy have been described. Thermann and Wollert favor the continuous irrigation therapy following a wound debridement also in cases of deep infection involving the graft. Complete wound healing was achieved in 13 of 20 cases (65.0 %) [7]. This method is usable if there is no large tissue defect and a primary wound closure is possible. Vacuum therapy alone for definitive wound closure in cases of a large tissue defect with exposed graft leads to an ineffective healing process. An unsatisfactory healing and reinfection rate were described [8,9]. As an alternative, we use the vacuum therapy as salvage procedure for decontamination and favor the definitive wound closure only by a well vascularized muscle flap.

References

1. Seeger JM (2000) Management of patients with prosthetic vascular graft infection. *Am Surg* 66: 166-177.
2. Wilson SE (2001) New alternatives in management of the infected vascular prosthesis. *Surg Infect (Larchmt)* 2: 171-175.
3. Zühlke HV, Harnoss BM (1988) *Septische Gefäßchirurgie. Überreuter-Wissenschaft, Wien.*
4. Armstrong PA, Back MR, Bandyk DF, Johnson BL, Shames ML (2007) Selective application of sartorius muscle flaps and aggressive staged surgical debridement can influence long-term outcomes of complex prosthetic graft infections. *J Vasc Surg* 46: 71-78.
5. Mixter RC, Turnipseed WD, Smith DJ Jr, Acher CW, Rao VK, et al. (1989) Rotational muscle flaps: a new technique for covering infected vascular grafts. *J Vasc Surg* 9: 472-478.
6. Silvestre L, Pedro LM, Fernandes E, Fernandes R, Silva E, Fernandes E, Fernandes J (2014) Rectus femoris muscle flap based on proximal insertion mobilization to cover a groin infected vascular graft. *J Vasc Surg* S0741-5214
7. Thermann F, Wollert U (2014) Continuous irrigation as a therapeutic option for graft infections of the groin. *World J Surg* 38: 2589-2596.
8. Dosluoglu HH, Loghmanee C, Lall P, Cherr GS, Harris LM, et al. (2010) Management of early (<30 day) vascular groin infections using vacuum-assisted closure alone without muscle flap coverage in a consecutive patient series. *J Vasc Surg* 5: 1160-1166.
9. Karl T, Storck M. Negative pressure wound therapy (NPWT). *Gefäßchirurgie* 17: 37-45.