

Microfilariae in Fine Needle Aspirates From a Coastal District of India: An Experience With Brief Review of Literature

Dr. Santosh T*

Department of Cytopathology, Seth GSMC & KEMH, Mumbai, Maharashtra

*Corresponding author: Dr. Santosh T, Fellow Cytopathology, Department of Cytopathology, Seth GSMC & KEMH, Mumbai, Maharashtra, Tel: +08895495670; Fax: +09584873660; E-mail: born_vss@yahoo.co.in

Received date: February 12, 2017; Accepted date: February 20, 2017; Published date: February 28, 2017

Copyright: © 2017 Dr. Santosh T. This is an open-access article distributed under the terms of the Creative Commons Attribution License, which permits unrestricted use, distribution, and reproduction in any medium, provided the original author and source are credited.

Abstract

Filariasis is a major public health problem in tropical countries like India. Conventional diagnosis is by demonstrating microfilariae (MF) in the peripheral blood smear. Nocturnal periodicity of the species endemic in India makes it difficult to find microfilariae in blood. Incidental detection of microfilariae (MF) in fine needle aspiration cytology (FNAC) smears of various sites in clinically unsuspected cases of filariasis without microfilariae in the peripheral blood has been rarely documented in Indian literature. We are reporting interesting detection of MF in 10 aspirates over a period of one year, from various sites as well as lesions ranging from inflammatory to malignancy. This article is intended to highlight that microfilaria can be a finding in clinically unsuspected cases and also without peripheral blood eosinophilia.

Keywords: Microfilaria; Adult worm; Embryoid bodies; FNAC; Malignancy; Body fluids; Ultrasonography

Introduction

Filariasis is a global problem. It is a major social and economic scourge in the tropics and subtropics of Africa, Asia, Western Pacific and parts of the America affecting over 83 countries [1].

More than 1.3 billion people live in areas where there is a risk of infection of which 120 million are infected and in need of treatment, including 40 million people with overt disease [1].

In India, lymphatic filariasis is a major public health problem and is increasing yearly due to mismanagement of the environment.

An estimated 600 million people are at risk of lymphatic filariasis infection in 250 endemic districts in 20 states/Union territories in India.

The disease is endemic throughout India but heavily infected areas are found in Uttar Pradesh, Bihar, Jharkhand, Andhra Pradesh, Odisha, Tamil Nadu, Kerala and Gujarat [1-3].

Filaria is a nematode belonging to the order spirurida and superfamily filarioidea [4]. The conventional diagnosis of filariasis relies on finding microfilariae on a peripheral blood smear. However, incidental detection of microfilariae in various cytological specimens has also led to the diagnosis in unsuspected case.

The finding of microfilaria in fine needle aspirates is uncommon [5]. The literature contains occasional reports of finding microfilariae in various locations; including the thyroid, breast, skin and soft tissue swellings, epididymis, salivary glands, the liver, lymph nodes, ovarian cysts, urine, endoscopic brushings and effusion fluids [6].

Even though the incidence is high, microfilaria in fine needle aspiration cytology (FNAC) smear and body fluids are unusual and it

is rare to find microfilariae along with smears aspirated from neoplastic lesions.

There are only few reported cases of coexistent microfilaria with neoplasm in the cytology literature. Adult worm lives in the lymph node while microfilaria circulates in peripheral blood.

The cause of appearance of microfilariae in tissue fluid and exfoliated surface material may be due to either lymphatic/vascular obstruction, extravasation due to scar/tumor or inflammation or tumors causing damage to the walls [7].

The present article describes the incidental finding of microfilaria in 10 unsuspected cases of FNAC.

Materials and Methods

This study was conducted at Department of Pathology, Maharaja Krishna Chandra Medical College, Berhampur, India over a 12 month period (Jan 2014-Dec 2014).

All the 10 cases in which microfilariae were detected incidentally in various cytospreads were included.

The smears were immediately fixed in 95% alcohol for H&E stain and Pap stain, air dried smears were evaluated using Diff Quick stain.

In case of cystic lesion the sample was centrifuged and sediment was spread over a slide with routine cytology staining.

Results

Total of 2926 (FNAC 2426, Fluid cytology 301, Scrape cytology 199) cases were performed and 10 cases of filariasis were diagnosed on routine FNAC material.

The age, sex and site distribution of the cases along with provisional diagnosis are listed (Table 1).

Case No	Age/sex	Complaints	Site	Provisional diagnosis	Final Diagnosis
1	22 M	Lymphadenopathy	Right axillary lymph node	Tuberculosis	Filarial lymphadenitis
2	13 M	Arm swelling	Left arm	Tuberculosis	Filarial nodule
3	41 F	Pleural fluid	Pleura	Malignant effusion	Malignant effusion with microfilariae
4	55 F	Bone marrow	Rt iliac spine	Malignancy (Metastatic deposit)	Metastatic adenocarcinomatous deposit with microfilariae
5	25 M	Lymphadenopathy	Inguinal region	Tuberculosis	Filarial lymphadenitis
6	36 M	Ascitic Fluid	Peritoneum	Malignancy	Inflammatory effusion - filarial
7	28 F	Breast mass	LUOQ	Fibroadenoma	Filarial granuloma
8	34 F	Breast mass	Subareolar	Abscess	Filarial abscess
9	36 F	Liver cyst	Liver	Hydatid cyst	Inflammatory cyst - Filarial
10	26 M	Arm swelling	Right arm	Tuberculosis	Filarial nodule

Table 1: Site distribution of cases with diagnosis.

In two cases, one bone marrow aspirate and one pleural effusion the incidental association of microfilariae was with a malignant disease i.e., metastatic deposit in marrow and malignant effusion while the rest were non-neoplastic. *Wuchereria Bancrofti* was the only species encountered identified by a sheath, which is much longer than the larval body and with the tail tip being free of nuclei.

The clinical presentations of these cases were varied most asymptomatic, ill to well defined mass lesions or symptoms of effusion.

No typical features of filariasis like fever with chill and rigor were elucidated even after careful history taking.

The aspirates were mostly insignificant except in two cases where it was hemorrhagic or purulent. The microscopic picture in each case is tabulated (Table 2).

Case No.	Site	Microscopic findings
1	Right axillary lymph node	Sheathed microfilariae in a mixed inflammatory cell comprised of eosinophils, polymorphs and histiocytes.
2	Left arm	A segment of adult worm packed with ova, ova with embryoid bodies, sheathed microfilariae in an inflammatory background comprised of eosinophils, polymorphs and histiocytes (Figure 1).
3	Pleural fluid	Sheathed microfilariae along with adenocarcinomatous cells, reactive mesothelial cells and mixed inflammatory cells.
4	Right iliac spine Bone Marrow	Metastatic adenocarcinomatous deposit with microfilariae (Figure 2).
5	Inguinal lymph node	Sheathed microfilariae in a mixed inflammatory cell comprised of eosinophils, polymorphs and histiocytes.
6	Peritoneal fluid	Sheathed microfilariae along with reactive mesothelial cells and mixed inflammatory cells.
7	Subareolar lump breast	Microfilariae in a granulomatous inflammatory background comprised of foreign body type giant cells and histiocytes (Figure 3).
8	LUOQ Breast	Sheathed microfilariae in a predominantly polymorphonuclear inflammatory cells and histiocytes.
9	Liver cyst	Centrifuged deposit of the USG guided aspirate on wet mount preparation showed sheathed microfilariae (Figure 4).
10	Right arm swelling	Sheathed microfilariae in a mixed inflammatory cell comprised of polymorphs and histiocytes.

Table 2: Microscopic observation in each case.

To summarize the microscopic pictures (Figures 1-4) all cases showed sheathed microfilaria with tail tip free of nuclei. Eosinophils were not the predominant inflammatory cells in most of the cases. In

the case of sub-areolar breast lump there was strong granulomatous inflammatory reaction with many foreign body type giant cells.

In two cases all stages of development of filarial worm was seen on the aspirate smears that includes the gravid body segment of the adult worm packed with the ova, ova containing the larva and microfilaria.

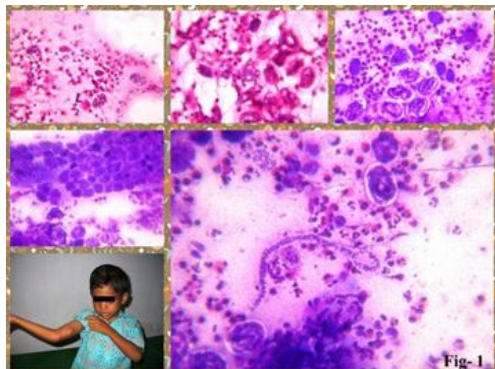


Figure 1: Swelling in left arm with cytosmears showing a segment of adult worm packed with ova, ova with embryoid bodies, sheathed microfilariae in an inflammatory background comprised of eosinophils, polymorphs and histiocytes (Diff Quik, x40).

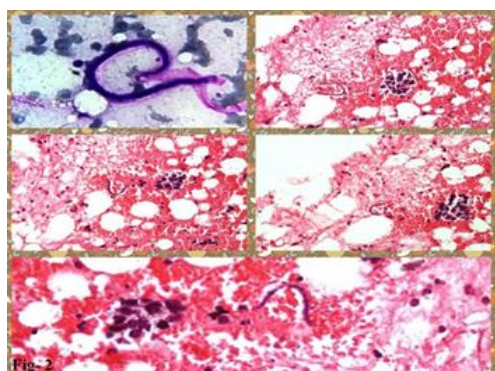


Figure 2: Right iliac spine Bone Marrow aspirate, cell block showing microfilariae with metastatic adenocarcinomatous deposits (Diff Quik x40, H&E x40).

Life cycle of the nematode includes two hosts, female culex is the intermediate host and humans are the definitive host. Microfilariae are the infective agent.

To summarize the microscopic pictures all cases showed sheathed microfilaria with tail tip free of nuclei. Eosinophils were not the predominant inflammatory cells in most of the cases. In the case of sub-areolar breast lump there was strong granulomatous inflammatory reaction with many foreign body type giant cells.

L3 larvae from mosquito enter the lymphatics of human beings and develop into adult worms that normally live in the lymphatics and release microfilaria into the peripheral blood to be taken up by another mosquito.

The most probable explanation to the finding of microfilariae in tissue fluids and body fluids is their extravasation secondary to lymphatic and vascular obstruction.

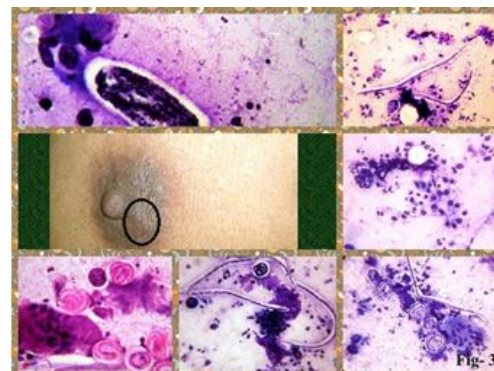


Figure 3: Subareolar lump in breast with cytosmears showing microfilariae in a granulomatous inflammatory background comprised of foreign body type giant cells and histiocytes (Diff Quik, x40).

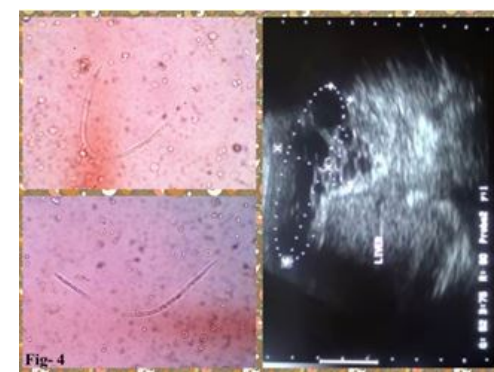


Figure 4: Liver cyst in USG with cytocentrifuged preparation showing microfilariae (Wet mount, x40).

Discussion

Filariasis is a major public health problem in many countries, including India [1]. Filariasis is caused by nematodes *Wuchereria bancrofti*, *Brugia malayi*, *B. timori*, *Onchocerca volvulus*, *Mansonella perstans*, *M. streptocerca*, *M. ozzardi*, *Dirofilaria conjunctivae*, *D. magalhaesi*, *D. immitis* and *Loa-loa*. *Wuchereria bancrofti* and *Brugia malayi* are the most common species seen in India. They are transmitted by the bite of the Culex mosquito [1,7]. In India filariasis is common in Uttar Pradesh, Bihar, Kerala, Jharkhand, Orissa, Tamil Nadu and Gujarat [1,2]. The present estimate suggests that over 120 million people in 80 countries are affected by filariasis and more than 1.1 billion people live in areas where there is risk of infection[1,2].

Life cycle of the nematode includes two hosts, female culex is the intermediate host and humans are the definitive host. Microfilariae are the infective agent. L3 larvae from mosquito enter the lymphatics of human beings and develop into adult worms that normally live in the lymphatics and release microfilaria into the peripheral blood to be taken up by another mosquito [4].

Lymphatics of lower limbs, retroperitoneal tissue, spermatic cord, epididymis and mammary glands are the commonest locations [5]. The clinical spectrum of manifestations are varied ranging from asymptomatic microfilaremia to acute lymphangitis, acute and chronic lymphadenitis leading to elephantiasis of limbs and genitalia and tropical pulmonary eosinophilia [8,9].

Diagnosis of filariasis can be clinically ascertained in endemic areas but the definitive diagnosis rests on demonstration of microfilariae in the peripheral blood [10]. Because of the nocturnal habit of the parasite night blood samples are ideal or alternatively a sample can be collected after a DEC provocation to increase the chance of getting the parasite. The most probable explanation to the finding of microfilariae in tissue fluids and body fluids is their extravasation secondary to lymphatic and vascular obstruction [5]. In most of the cases in the present study the detection of microfilariae was incidental.

A peripheral smear stained with Giemsa is the definitive diagnosis method for filariasis. Now a days QBC method is an alternative to this with increased chance of getting the parasite as it concentrates them to the particular region. Though FNAC is not routinely utilized for clinically suspected cases of filariasis, but microfilaria has been detected at various unusual sites either associated with other diseases or independently in unsuspected cases [7].

Microfilaria has been found at various sites like breast, neck lymph nodes, thyroid, testis, epididymis, axillary swellings, subcutaneous swellings, effusions, cervical scrape smears, bronchial washing, soft tissue, bone marrow, leprosy and others [11-15]. Microfilariae have been reported in association with neoplastic lesions such as hemangioma of liver [16], Ewing's sarcoma of bone [17], squamous cell carcinoma of maxillary antrum [18], anaplastic astrocytoma of thalamus, low grade astrocytoma of C6-D1 spinal segment, Metastatic carcinoma breast to bone marrow, cranipharyngioma of third ventricle and non- Hodgkin lymphoma [19].

Conclusion

In endemic areas, the diagnosis of filariasis should be considered in the differential diagnosis of swellings. Even in the absence of clinical indications and absence of eosinophils in peripheral smears, microfilaria can be detected at any site. This highlights the importance of careful screening of fine needle aspiration smears in asymptomatic patients.

References

1. K Park (2011) Epidemiology of communicable diseases. Park's text book of preventive and social medicine, pp: 245-246.

- Gupta S, Gupta R, Bansal B, Singh S, Gupta K, et al. (2010) The significance of the incidental detection of filariasis on aspiration smears: a case series. *Diagn Cytopathol* 38: 517-520.
- Gole S, Satyanarayana V, Gole G (2013) Unusual cytological findings in breast aspirates: Case studies of microfilariae with review of literature. *The Internet Journal of Pathology* 14: 43-45.
- Chatterjee KD (1980) Helminthology. In: Chatterjee KD (ed). *Parasitology, protozoology and helminthology*. pp: 174-182.
- Sainath KA, Akshatha N (2011) Microfilaria and filarial granulomas from fine needle aspirates: a study of 25 cases. *Southeast Asian J Trop Med Public Health* 42: 1351-8.
- Yenkeshwar PN, Dinkar T, Sudhakar K, Bhabate K (2006) Microfilariae in fine needle aspirates: A report of 22 cases. *Indian J Pathol Microbiol* 49: 365-369.
- Hemali JT, Vasudha MB, Peeyush KS, Varsha M (2013) Cytodiagnosis of bancroftian microfilariae at various sites in an endemic area. *International Journal of Scientific Research* 2: 277-278.
- Mitra SK, Mishra RK, Verma P (2009) Cytological diagnosis of microfilariae in filariasis endemic areas of eastern Uttar pradesh. *J Cytol* 26: 11-14.
- Srikanth S (2014) Microfilaria in forearm swelling aspirate: An unusual finding. *J Mahatma Gandhi Inst Med Sci* 19: 59-61.
- Rawat V, Rizvi G, Sharma N, Pandey H (2009) An unusual presentation of Wuchereria bancrofti infection. *Indian J Med Microbiol* 27: 382-383.
- Kapila K, Verma K (1996) Diagnosis of parasites in fine needle breast aspirates. *Acta Cytol* 40: 653-656.
- Sodhani P, Nayar M (1989) Microfilaria in thyroid aspirate smear: An incidental finding. *Acta Cytol* 33: 942-994.
- Pandit A, Prayag AS (1993) Microfilaria in thyroid smear : An unusual finding. *Acta cytol* 37: 845-846.
- Rani S, Beohar PC (1981) Microfilaria in bone marrow aspirate: A case report. *Acta Cytol* 25: 425-429.
- Meharotra R, Singh M (2000) Diagnosis of microfilaria in testicular FNAB. *Acta Cytol* 44: 283-284.
- Gupta S, Sodhani P, Jain S, Kumar N (2001) Microfilariae in association with neoplastic lesions: Report of five cases. *Cytopathol* 12: 120-126.
- Ahluwalia C, Chaudhary M, Bajaj P (2003) Incidental detection of microfilaria in aspirates from Ewing's sarcoma of bone. *Diagn Cytopathol* 29: 31-32.
- Mohan G, Chaturvedi S, Misra PK (1998) Microfilaria in a fine needle aspirate of primary solid malignant tumor of the maxillary antrum- A case report. *Acta Cytol* 42: 772-774.
- Aron M, Kapila K, Sarkar C, Verma K (2002) Microfilaria of Wuchereria bancrofti in cyst fluid of tumors of the brain: A report of 3 cases. *Diagn Cytopathol* 26: 158-162.