

Exercise Echocardiography Findings and Outcome in Patients with Right Ventricular Dilation not Related to Left-Sided Heart Disease

Jesús Peteiro*, Alberto Bouzas-Mosquera, Juan C Yañez, Dolores Martinez and Jose M Vazquez-Rodriguez

Department of Cardiology, University Hospital Complex of A Coruña (CHUAC), Institute of Biomedical Research of A Coruña (INIBIC), University of A Coruña, A Coruña, Spain

Abstract

Objective: Symptoms may be similar in patients with heart or lung disease. Thus, patients with lung disease are occasionally referred for evaluation by exercise echocardiography (ExE). We aimed to study the clinical, ExE data and outcome of patients with right ventricular (RV) dilation not explained by left ventricular (LV) heart disease.

Methods: Retrospective analysis of RV dysfunctional data in absence of LV heart disease in patients submitted to an ExE.

Results: Data on RV dilation in absence of LV heart disease were found in 21 of 18,400 ExE studies (0.11%). In 4 of the 21 patients (19%) RV function and systolic pulmonary artery pressure were normal at rest. However, exercise induced RV dysfunction and/or elevated systolic pulmonary artery pressure in all of these 4 patients. During follow-up of 5.2 ± 5.7 years 11 patients died (52%), most of them of respiratory causes (73%), being pulmonary thromboembolism (PTE) (38%) the most frequent final diagnosis.

Conclusion: RV dysfunction in absence of LV disease is rare among patients referred for ExE. ExE is of value as sometimes abnormalities on RV function arise only with exercise

Keywords: Exercise echocardiography; Right ventricular function; Lung disease

Introduction

Patients who complain of symptoms during exercise, like chest pain or dyspnea are occasionally referred for evaluation by exercise echocardiography (ExE). Some of them may have no coronary artery disease (CAD) at all, but chronic or subacute lung disease instead. Indeed several findings are usually capable of distinguish cardiac from lung disease at rest but other specific findings might only arise at exercise. Of particular interest is the diagnosis of pulmonary thromboembolism (PTE) because specific treatment may improve survival [1]. Our aim was to review the diagnosis and outcome of patients with right ventricular dilation not associated to left ventricular disease that were referred for ExE to our institution.

Methods

From a total of 18,400 consecutive patients having a first ExE performed at our institution for clinical reasons between March 1995 and July 2015 those with moderate or severe right ventricular dilation at either rest or exercise echocardiography were considered for entering the study. Among them, patients with abnormal ExE (resting or exercise induced wall motion abnormalities, $n=18$), mitral or aortic significant valvopathies ($n=32$), clinical diagnosis of cardiomyopathy ($n=63$), or congenital heart disease ($n=2$) were excluded. The final included population consisted of 21 patients whose ExE results, further diagnostic tests and outcome were revised. Demographic and clinical data, as well as stress testing results, were entered in our database at the time of the procedures. ExE data were acquired and analyzed by cardiologists not involved in patient care. The investigator coding the events was blinded to all the ExE data.

ExE was performed on a treadmill according to protocols adjusted to the clinical characteristics of the patients (Bruce protocol 71%, modified protocols 29%). Exercise end points included physical exhaustion, significant arrhythmia, severe hypertension (systolic BP >240 mm Hg or diastolic BP >110 mm Hg), severe hypotensive response (decrease >20 mm Hg), and symptoms during exercise. Ischemic ECG was defined

as the development of ST-segment deviation of ≥ 1 mm which was horizontal or down sloping away from the isoelectric line 80 ms after the J point, in patients with normal baseline ST segments. The ECG was considered non-diagnostic in the presence of left bundle branch block, preexcitation, paced rhythm, repolarization abnormalities or treatment with digoxin. Positive exercise testing was defined as chest pain during the test and/or ischemic ECG abnormalities in patients with diagnostic ECG. A maximal test was defined as the achievement of at least 85% of the maximal age predicted heart rate (MAPHR), otherwise the test was considered submaximal. All patients gave informed consent.

Echocardiography was performed from the apical long-axis, apical four and two-chambers, parasternal long-axis, and parasternal short-axis views at rest, peak and post-exercise, as described [2,3]. Images at rest were taken in the decubitus lateral position, at peak exercise with the patient still exercising on the treadmill. The peak exercise study was used for ischemia detection whereas Doppler assessment was done during the immediate post-exercise period with the patients again lying on the table (within 1 min). At this time continuous-wave Doppler assessment of the tricuspid valve velocity spectrum in systole was performed in patients with tricuspid regurgitation signal. Raw data were stored digitally for postprocessing analysis. Regional wall motion analysis was performed with a 16-segment model of the left ventricle [4,5]. LV ejection fraction was measured visually [6] or by the biplane Simpson's method. RV function parameters assessed at rest

*Corresponding authors: Jesus Peteiro, Department of Cardiology, University Hospital Complex of A Coruña (CHUAC), The xubis, 84, 15006, A Coruña, Spain, Tel: 34981917859; Fax: 34981178258; E-mail: pete@canalejo.org

Received April 19, 2017; Accepted May 23, 2017; Published May 26, 2017

Citation: Peteiro J, Bouzas-Mosquera A, Yañez JC, Martinez D, Vazquez-Rodriguez JM (2017) Exercise Echocardiography Findings and Outcome in Patients with Right Ventricular Dilation not Related to Left-Sided Heart Disease. J Cardiovasc Dis Diagn 5: 279. doi: [10.4172/2329-9517.1000279](https://doi.org/10.4172/2329-9517.1000279)

Copyright: © 2017 Peteiro J, et al. This is an open-access article distributed under the terms of the Creative Commons Attribution License, which permits unrestricted use, distribution, and reproduction in any medium, provided the original author and source are credited.

Age (y)	64 ± 14
Male gender, n (%)	13 (62)
Diabetes mellitus, n (%)	5 (24)
Hypertension, n (%)	8 (38)
Hypercholesterolemia, n (%)	11 (52)
Smoking habit, n (%)	4 (19)
History of CAD, n (%)*	3 (14)
Abnormal resting ECG, n (%)	7 (33)
Beta-blockers at the time of the ExE, n (%)	1 (5)
Nitrates, n (%)	6 (29)
Calcium channel blockers, n (%)	2 (10)
ACEI/ARA	2 (10)

ACEI: Angiotensin converting enzyme inhibitors ARA: Angiotensin receptor antagonists

Table 1: Clinical baseline characteristics.

Parameters	Rest	Exercise
Heart rate (bpm)	81 ± 15	136 ± 24
Resting systolic blood pressure (mmHg)	134 ± 21	159 ± 36
LVEF (%)	59 ± 5	66 ± 5
E/e' (n=5)	7.8 ± 2.5	9.2 ± 1.6
sPAP (mmHg)	61 ± 24	92 ± 36
RV diameter (cm)	3.5 ± 0.9	3.6 ± 1.0
RV end-diastolic volume (cm ³)	41 ± 24	53 ± 26
RVEF (%)	42 ± 13	48 ± 16
RVEF<60%, n (%)	16 (76%)	13 (62%)
TAPSE (mm)	16.4 ± 5.8	17.5 ± 6.0
TAPSE <20 mm, n (%)	13 (62%)	9 (43%)

E/e': ratio of LV inflow early transmitral wave to systolic annulus early diastolic wave
 RV: right ventricle
 sPAP: systolic pulmonary artery pressure
 TAPSE: tricuspid annular plane systolic excursion

Table 2: Resting and exercise hemodynamic and echocardiographic parameters.

Age/gender	Reasons for ExE	Resting ECG	METs	Symptoms during ExE	sPAP at rest (mmHg)	sPAP at exercise (mmHg)	Final Dx	Main Tests and Results	Death	Cause of death
28/M	CTx evaluation	AF	9	no	20	na	CTx, RV failure	V/Q scan (0)	(+)	CTx: RV failure, probable PTE
45/M	Chest pain+ dyspnea	normal	7	no	53	na	Porto-PHT	CTPA (0)	(-)	
52/F	Chest pain	normal	11	no	40	78	Restrictive lung disease		(+)	Acute respiratory failure
53/F	Chest pain	normal	7	angina	90	90	PTE	CTPA (1) CA (0)	(-)	
54/M	Chest pain	ST abnormalities	3	no	77	98	Restrictive lung disease		(+)	Brain haemorrhage
54/F	Dyspnea	normal	2	dyspnea	49	na	PTE	CTPA (1)	(-)	
57/F	Chest pain	normal	4	dyspnea	94	180	Primary PHT	CTPA (0)	(+)	Post-operative LTx failure
57/M*	Chest pain	normal	4	no	na	na	no dx	V/Q scan (0) CA (0)	(+)	Lung cancer
57/M	Chest pain	ST abnormalities	9	dizziness	na	na	PTE	MRA (1)	(-)	
65/M	Chest pain+ dyspnea	ST abnormalities	5	dyspnea	110	144	PTE	CTPA (1)	(+)	PTE
65/F*	Chest pain+ dyspnea	normal	7	angina+ dyspnea	46	110	Primary PHT	CTPA (0) MR (0) V/Q scan (0)	(-)	
69/M	Chest pain	normal	5	dyspnea	80	100	PTE	CTPA (1)	(-)	
70/M	Chest pain	normal	5	angina + dyspnea	70	62	PTE	CTPA (1)	(-)	
72/M	Chest pain	normal	7	no	64	120	PTE	V/Q scan (1)	(+)	PTE

and at exercise were RV diameters in the 4-chamber apical or long axis parasternal views, RV ejection fraction (RVEF) in the 4 chamber apical view, and tricuspid annular plane systolic excursion (TAPSE) [7]. LV septal shift at rest and at exercise was also examined. Beta-blocking agents were withdrawn for the ExE in most patients.

Follow-up in the study cohort was obtained by review of hospital databases, medical records and death certificates, as well as by telephone interviews when necessary. Any causes of mortality, cardiac death, revascularizations during follow-up and non-fatal MI were investigated during follow-up. TPE diagnosis was performed according to suggestive findings by either computed tomography pulmonary angiogram (CTPA), magnetic resonance angiography (MRA) or ventilation perfusion scan (V/Q) in a clinically relevant context.

Categorical variables were reported as % and comparison between groups based on the χ^2 test. Continuous variables were reported as mean \pm 1 standard deviation and intergroup comparisons made by the test t de Student. A p value <0.05 was considered significant. Statistical analyses were performed using SPSS software, version 21.0 (IBM Corp., Armonk, NY, USA).

Results

The baseline clinical characteristics and ExE results of the 21 patients are shown in Tables 1 and 2, whereas Table 3 is a summary of these clinical and ExE characteristics, further tests and outcome in the entire cohort. Half of the patients had symptoms during the exercise testing, including dyspnea (n=7), angina (n=3), dizziness (n=1) and syncope (n=1). The ECG during the exercise was considered positive in only 1 patient (5%) and non-diagnostic in 7 (33%). The maximal achieved workload (METs) was 5.9 \pm 2.8 and the test was submaximal in 9 patients (43%).


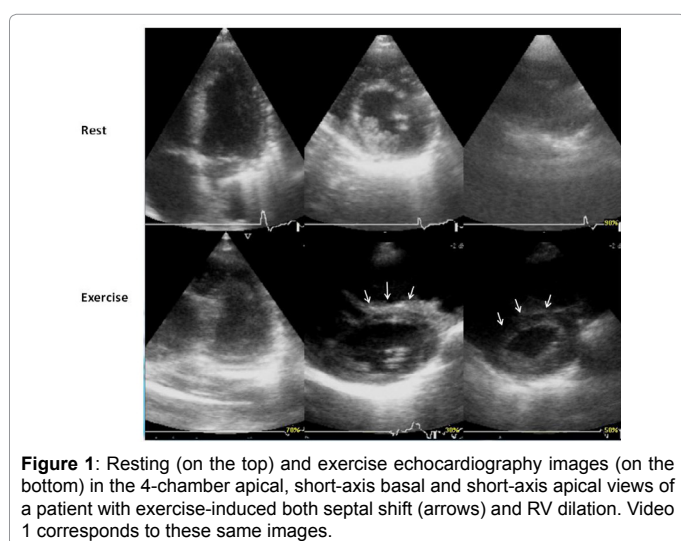
During follow-up of 5.2 \pm 5.7 years 11 patients died (52%), most

74/F*	Dyspnea	LBBB	10	no	50	64	COPD	CTPA (0) V/Q scan (0)	(-)	
76/F	Chest pain	normal	2	syncope	70	70	PTE	V/Q scan (1)	(+)	ARI
76/M	Chest pain	normal	2	angina	55	94	Restrictive lung disease +COPD	CTPA (0)	(+)	ARI
78/M*	Chest pain	AF, LBBB	10	dyspnea	na	67	no dx		(+)	Unknown
78/F	Chest pain	normal	7	no	29	34	no dx		(-)	
83/M	Chest pain	normal	3	no	70	110	COPD	CTPA (0)	(+)	Sudden death
88/M	Dyspnea	LBBB	4	no	30	55	no dx		(-)	

Abbreviations: AF: Atrial fibrillation; ARI: Acute respiratory infection; CA: Coronary angiography; CTx: Cardiac transplantation; CTPA: Computed tomography pulmonary angiogram; CPOD: Chronic obstructive pulmonary disease; Dx: Diagnosis; ExE: Exercise echocardiography; F: Female gender; LBBB: Left bundle branch block; LTx: Lung transplantation; M: Male gender; MRA: Magnetic resonance angiography; PHT: Pulmonary hypertension; PTE: Pulmonary thromboembolism; sPAP: systolic pulmonary artery pressure; V/Q: Ventilation perfusion scan; (0): negative findings; (1) positive findings.

*abnormal findings developing just with exercise

Table 3: Summary of clinical characteristics, exercise results, further tests and outcome in the 21 patients with moderate or severe right ventricular dilatation and absence of associated left ventricular heart disease during ExE.



of them of non-cardiovascular causes (73%). Non-fatal MI was reported in just one patient. Data for quantitative analysis of RV and LV dimension and for ventricular septal shift at rest and at exercise were available for 16 patients. In 6 of them, ventricular septal shift was only seen at exercise (Figure 1 and Video 1), and in 3 at both rest and exercise. Patients with septal shift at both conditions had the highest sPAP at rest and at exercise, and those without septal shift at any condition the lowest, whereas those with exercise-induced septal shift had intermediate values (Figure 2). In 4 patients (19%) RV function was normal at rest and there was not elevated sPAP. However, exercise induced RV dysfunction in 2 of them, and an exercise sPAP >60 mmHG was seen in 3, in one of them up to 110 mmHg, along with

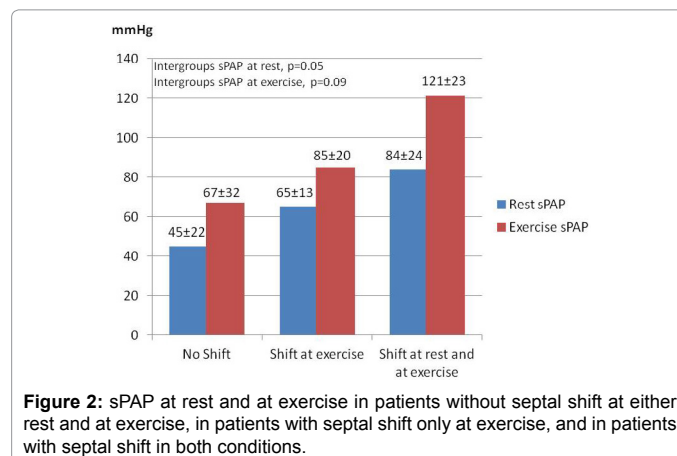
exercise-induced septal shift. Other 4 patients did not have any sign of RV suffering at rest above RV dilation. In them, the sPAP was ≤ 40 mmHg and there was no septal shift at rest. However, exercise induced significant sPAP and/or septal shift in all these 4 patients.

The most frequent final diagnosis was pulmonary thromboembolism (PTE) (8/21, 38%). Symptoms during exercise were more prevalent in patients with PTE than in those without (88% vs. 31%, $p=0.02$), and both RVEF and sPAP at rest were worse in patients with PTE ($33\% \pm 9\%$ vs. $48\% \pm 12\%$, $p=0.01$; and 76 ± 20 mmHg vs. 52 ± 22 mmHg, $p=0.03$, respectively).

Discussion

ExE is widely used for assessment of coronary and valvular heart disease. For these aims focus is mainly made on the LV, leaving the RV less studied. When everything is normal on the LV side in patients that may have symptoms that are similar in heart and lung pathologies such as dyspnea or chest pain, suspicion of RV disease may arise.

The main findings of this study are as follows. First, significant RV dilation is a rare condition in patients with resting and exercise echocardiography showing absence of LV disease, accounting for only 0.11% of the ExE studies. However, when present, severe lung disease associated to pulmonary hypertension and to ominous outcome is frequent. This is not new as it has been known for long that outcome is poor when the RV suffers due to lung disease [8]. Patients with lung disease may have exercise-induced pulmonary hypertension, leading ultimately to RV suffering. Although most of our patients had already any of these abnormalities at rest, they used to impair with exercise. Also, in a few cases, they arose only with exercise. In four of them (19%)



RV dysfunction, septal shift, or pulmonary hypertension developed exclusively at exercise. Previous isolated case-report studies have shown RV dilation and pulmonary hypertension detected exclusively at exercise in patients with PTE [9,10]. The advantage of suspecting PTE lies on specific treatment available for it [1]. According to our results, among patients referred for ExE, PTE should be suspected in those with absence of LV heart disease, symptoms during the test and moderate to severe pulmonary hypertension at either rest or exercise. However, among our 4 patients with RV dysfunctional data developed with exercise, PTE was just confirmed in one case (Table 3).

On the other hand, our data confirms previous reports observing the small number of cardiac events in patients with a normal ExE [1,2] as only one patient of our cohort died of suspected cardiac causes (sudden death) and only 1 had a myocardial infarction during follow-up. Mortality was dramatically high but it was mainly due to lung disease. These results emphasize the need for focusing in lung disease assessment when an exercise echocardiogram confirms absence of LV disease but presence of RV dysfunction at rest or at exercise. Also, our findings suggest that ExE is an useful test for evaluation of patients who, despite of known lung disease in some of them, concerns about the presence of concomitant CAD may still exist.

Limitations include that this is a small retrospective study of subjects in whom the examiner described RV dilation at rest or during exercise in the ExE report. The low number of patients without left heart disease that finally had RV dilatation during ExE makes any conclusion statistically difficult. We have included only patients with at least moderate RV dilation either at rest or at exercise during an ExE study. Minor degrees of RV dilation might not have been informed, although if reported and used for this study, the results regarding outcome would have been likely better. Indeed, we could have lost patients with RV abnormalities not well studied at either rest or exercise, as we mainly focus on LV function during an ExE. RV dilation was visually estimated at the time of the ExE, rather than rightly quantified, and therefore misclassification might have occurred in some cases.

Also, data on RV function and sPAP at rest and at exercise were unfortunately not available for all patients.

Conclusion

RV dysfunction in absence of LV disease is rare among patients referred for ExE. However, ExE is of value as sometimes abnormalities on RV function arise only with exercise.

References

1. Kim NH, Delcroix M, Jenkins DP, Channick R, Darteville P, et al. (2013) Chronic thromboembolic pulmonary hypertension. *J Am Coll Cardiol* 62: D92-D99.
2. Peteiro J, Bouzas-Mosquera A, Broullón FJ, Garcia-Campos A, Pazos P, et al. (2010) Prognostic value of peak and post-exercise treadmill exercise echocardiography in patients with known or suspected coronary artery disease. *Eur Heart J* 31: 187-95.
3. Bouzas-Mosquera A, Peteiro J, Alvarez-García N, Broullón FJ, Mosquera VX, et al. (2009) Prediction of mortality and major cardiac events by exercise echocardiography in patients with normal exercise electrocardiographic testing. *J Am Coll Cardiol* 53: 1981-1990.
4. Lang RM, Badano LP, Mor-Avi V, Afilalo J, Armstrong A, et al. (2015) Recommendations for cardiac chamber quantification by echocardiography in adults: An update from the American Society of Echocardiography and the European Association of Cardiovascular Imaging. *J Am Soc Echocardiogr* 28: 1-39.e14.
5. Hoffmann R, Lethen H, Marwick T, Rambaldi R, Fioretti P, et al. (1998) Standardized guidelines for the interpretation of dobutamine echocardiography reduce interinstitutional variance in interpretation. *Am J Cardiol* 82: 1520-1524.
6. Stamm RB, Carabello BA, Mayers DL, Martin RP (1982) Two-dimensional echocardiographic measurement of left ventricular ejection fraction: Prospective analysis of what constitutes an adequate determination. *Am Heart J* 104: 136-144.
7. Rudski LG, Lai WW, Afilalo J, Hua L, Handschumacher MD, et al. (2010) Guidelines for the Echocardiographic Assessment of the Right Heart in Adults: A Report from the American Society of Echocardiography Endorsed by the European Association of Echocardiography, a registered branch of the European Society of Cardiology, and the Canadian Society of Echocardiography. *J Am Soc Echocardiogr* 23: 685-713.
8. Alajaji W, Baydoun A, Al-Kindi SG, Henry L, Hanna MA, et al. (2016) Digoxin therapy for cor pulmonale: A systematic review. *Int J Cardiol* 223: 320-324.
9. Case BC, Zemedkun M, Sangkharat A, Taylor AJ, Srichai MB (2015) Pulmonary embolism diagnosed from right heart changes seen after exercise stress echocardiography. *Circ Cardiovasc Imaging* 8: e003506.
10. Ramanath VS, Lacomis JM, Katz WE (2004) Diagnosis of pulmonary embolism by acute right heart morphologic and hemodynamic changes observed during exercise stress echocardiography. *J Am Soc Echocardiography* 17: 1005-1008.

Citation: Peteiro J, Bouzas-Mosquera A, Yañez JC, Martínez D, Vazquez-Rodriguez JM (2017) Exercise Echocardiography Findings and Outcome in Patients with Right Ventricular Dilation not Related to Left-Sided Heart Disease. *J Cardiovasc Dis Diagn* 5: 279. doi: [10.4172/2329-9517.1000279](https://doi.org/10.4172/2329-9517.1000279)

OMICS International: Open Access Publication Benefits & Features

Unique features:

- Increased global visibility of articles through worldwide distribution and indexing
- Showcasing recent research output in a timely and updated manner
- Special issues on the current trends of scientific research

Special features:

- 700+ Open Access Journals
- 50,000+ Editorial team
- Rapid review process
- Quality and quick editorial, review and publication processing
- Indexing at major indexing services
- Sharing Option: Social Networking Enabled
- Authors, Reviewers and Editors rewarded with online Scientific Credits
- Better discount for your subsequent articles

Submit your manuscript at: <http://www.omicsonline.org/submission>