

## Development of Psoriasis Vulgaris in a Chronic Myeloid Leukemia Patient on Second-Generation Tyrosine Kinase Inhibitor Therapy

Shinto Francis Thekkudan and Soniya Nityanand\*

Department of Hematology, Sanjay Gandhi Post Graduate Institute of Medical Sciences, Uttar Pradesh, India

\*Corresponding author: Dr. Soniya Nityanand, Professor and Head, Department of Hematology, Sanjay Gandhi Post Graduate Institute of Medical Sciences, Lucknow - 226014, Uttar Pradesh, India, Tel: +91-522-2494291; E-mail: [soniya\\_nityanand@yahoo.co.in](mailto:soniya_nityanand@yahoo.co.in)

Received date: March 09, 2017; Accepted date: March 29, 2017; Published date: April 05, 2017

Copyright: © 2017 Thekkudan SF, et al. This is an open-access article distributed under the terms of the Creative Commons Attribution License, which permits unrestricted use, distribution, and reproduction in any medium, provided the original author and source are credited.

### Abstract

Development of psoriasis during Imatinib therapy has been described only as few case reports. Psoriasis developing during Nilotinib therapy is also rare, with only two cases reported. In psoriasis, the suppressor activity of T-regulatory cells is decreased, either due to a reduction in the number or due to a reduced ability of T-regulatory cells to produce suppressive cytokines. Imatinib and Nilotinib inhibited the proliferation and immunosuppressive effect of T-regulatory cells in a dose dependent manner. This is the first case report of Dasatinib causing worsening of Psoriasis vulgaris, possibly due to the more potent action of Dasatinib on T regs. Most cases can be managed without any dose reductions in tyrosine kinase inhibitor therapy along with topical therapies and oral methotrexate.

**Keywords:** Psoriasis vulgaris; Chronic myeloid leukemia; Tyrosine kinase inhibitors; Nilotinib; Dasatinib; Regulatory T cells

### Abbreviation

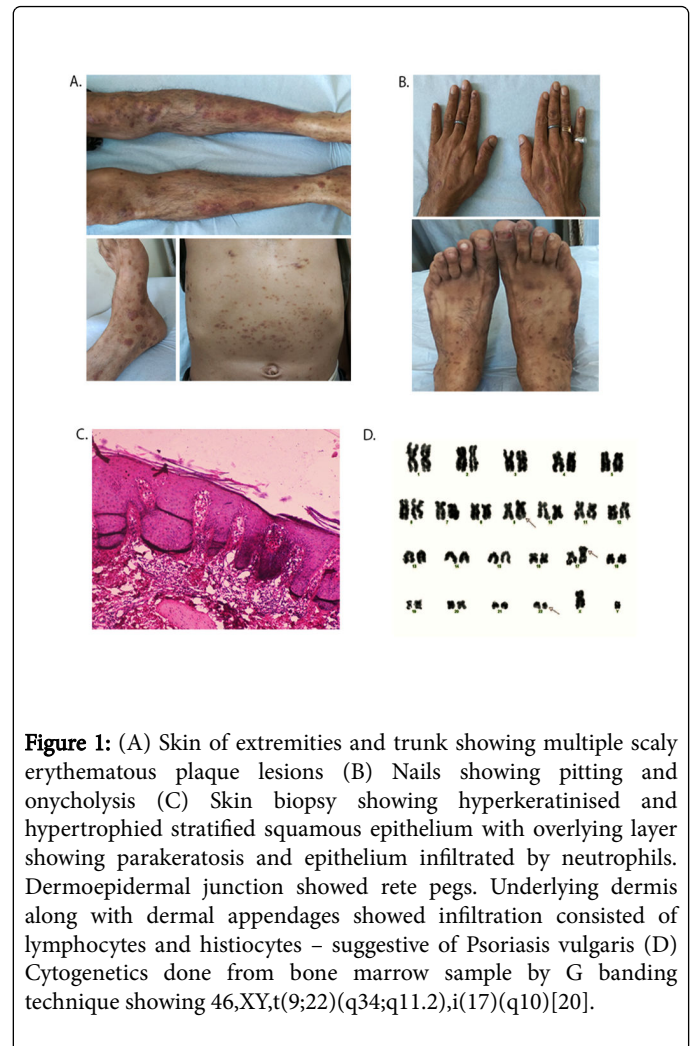
TKI: Tyrosine Kinase Inhibitor; CML: Chronic myeloid leukemia; T-regs: Regulatory T cells

### Introduction

Cutaneous side effects are well described with TKI therapy [1]. Development of psoriasis during Imatinib therapy has been reported only in a few case reports [2-6]. Nilotinib and Dasatinib are second-generation tyrosine kinase inhibitors, approved in patients who have failed or are intolerant to Imatinib and also as first line therapy in CML. There are only 2 case reports till date, on development of psoriasis with Nilotinib therapy [7,8] and none with Dasatinib. Here we describe development of psoriasis in a CML patient on Nilotinib, which further worsened when therapy was switched from Nilotinib to Dasatinib. Even though the mechanism underlying the pathogenesis of psoriasis on TKI therapy is largely not well understood, the main proposed theory is TKI induced T-reg's suppression.

### Case Report

A 39-year-old male was diagnosed to have CML - chronic phase in November 2008, and started on Imatinib 400 mg per day, on which he achieved major molecular remission and maintained it till February 2013. Thereafter, he developed secondary Imatinib resistance with loss of major molecular response. Kinase domain mutation analysis at that point of time showed no mutations. He was switched to Nilotinib at 400 mg twice daily. In November 2014, he developed insidious onset erythematous itchy lesions initially over extremities, later spreading on to trunk. No joint symptoms. On examination, he had multiple erythematous plaques like lesions, with occasional silvery white scales (Figure 1A). Nail changes in form of pitting and onycholysis were also noted (Figure 1B).



**Figure 1:** (A) Skin of extremities and trunk showing multiple scaly erythematous plaque lesions (B) Nails showing pitting and onycholysis (C) Skin biopsy showing hyperkeratinised and hypertrophied stratified squamous epithelium with overlying layer showing parakeratosis and epithelium infiltrated by neutrophils. Dermoepidermal junction showed rete pegs. Underlying dermis along with dermal appendages showed infiltration consisted of lymphocytes and histiocytes – suggestive of Psoriasis vulgaris (D) Cytogenetics done from bone marrow sample by G banding technique showing 46,XY,t(9;22)(q34;q11.2),i(17)(q10)[20].

Systemic examination was within normal limits. Skin biopsy showed hyperkeratinised and hypertrophied stratified squamous epithelium with overlying layer showing parakeratosis and epithelium infiltrated by neutrophils. Dermoepidermal junction showed rete pegs. Underlying dermis along with dermal appendages showed infiltration consisted of lymphocytes and histiocytes, suggestive of Psoriasis (Figure 1C). He was started on topical steroids along with a local application of emollients and paraffin, with which his lesions stabilized. He was continued on Nilotinib at the same dose.

In January 2015, due to his progressive rise in BCR ABL transcript ratio he was put on Dasatinib 50 mg BD. The psoriatic lesions worsened and hence oral methotrexate was added. But due to profound myelosuppression, methotrexate had to be discontinued and he was continued only on topical steroids and emollients. The skin condition plateaued. In January 2016, he developed a worsening in his anemia and thrombocytopenia with leukocytosis. Dasatinib was discontinued and the disease status was reevaluated with bone marrow examination, which showed the disease to be in accelerated phase with 12% blasts. BCR ABL (IS) transcript was 62.6%. G banding cytogenetics from bone marrow showed 46,XY, t(9;22)(q34;q11.2), i(17)(q10)[20] (Figure 1D). Kinase domain mutation analysis showed L298W SH3 binding domain mutation along with K263N and Q316 frame shift deletions. His skin lesions showed significant improvement during the ensuing three-week period of discontinuation of Dasatinib due to cytopenia. Later Dasatinib was restarted in a low dose 50 mg once daily and gradually escalated to 50 mg BD. Topical steroids and emollients were continued. Considering the disease progression, he is presently planned for matched sibling donor hematopoietic stem cell transplantation.

## Discussion

In psoriasis, the suppressor activity of T-reg cells is decreased, either due to a reduction in the number of these cells or due to a reduced ability of T-reg cells to produce suppressive cytokines or because of a "resistance" of T effector cells to their inhibition [9]. Chen et al. demonstrated that Imatinib and Nilotinib inhibited the proliferation and immunosuppressive effect of T-reg cells in a dose dependent manner [10,11]. Similarly, Fei et al. have demonstrated that Nilotinib suppressed proliferation and function of T-reg cells in a higher concentration in vitro (>10  $\mu$ M), but not at clinically relevant doses [12]. Aggravation or development of psoriasis during course of Imatinib therapy has been described previously [2-6]. In contrary, Nagayama et al. reported a case of improvement in psoriatic lesions during therapy with Imatinib [13]. Psoriasis developing during Nilotinib therapy has been described in only two case reports. Nagai et al. described first case of psoriasis developing 26 months of Nilotinib therapy and concluded that Nilotinib possibly inhibits the function of T-reg cells [7]. They tried to ascertain the percentage of CD45 (+), CD4 (+), CD25 (+) cells, corresponding to the T-reg fraction and found a relative increase of the same when compared to healthy subjects. The psoriatic lesions stabilized on topical activated vitamin D3 derivative and corticosteroid. Even though they haven't assessed the T reg cell activity, they concluded that if T-regs are really the key player then Dasatinib might have a higher potential for development of psoriasis. Meanwhile, Kaur et al described a case of psoriasis after 3 months of Nilotinib therapy, which improved with oral methotrexate along with topical steroids [8]. In both cases Nilotinib was continued without dose

reductions. Our patient developed psoriasis after 12 months of Nilotinib therapy. Switching to Dasatinib aggravated his psoriatic lesions reflecting its more potent action on T regs, which supports the findings of Fei et al. [14]. Since oral methotrexate induced severe myelosuppression he couldn't be continued on the same for prolonged duration. Discontinuation of Dasatinib, for the period of cytopenias, led to an improvement in the skin lesions, which again highlights the causal association.

## Conclusion

Prompt recognition of dermatological side effects is essential in patients on TKI. Most cases can be managed without any dose reductions in TKI along with topical therapies and/or oral methotrexate. Further studies are needed to ascertain the exact immune mechanisms leading to development of psoriasis in patients treated with TKI's.

## References

1. Brazzelli V, Grasso V, Borroni G (2013) Imatinib, dasatinib, and nilotinib: A review of adverse cutaneous reactions with emphasis on our clinical experience. *J Eur Acad Dermatol Venereol* 27: 1471-1480.
2. Shimizu K, Kuroda H, Kida M (2005) Psoriasis vulgaris exacerbated by imatinib therapy in chronic myelogenous leukemia. *Rinsho Ketsueki* 46: 1152-1155.
3. Dickens E, Lewis F, Bienz N (2009) Imatinib: a designer drug, another cutaneous complication. *Clin Exp Dermatol* 34: 603-604.
4. Woo SM, Huh CH, Park KC, Youn SW (2007) Exacerbation of psoriasis in a chronic myelogenous leukemia patient treated with imatinib. *J Dermatol* 34: 724-726.
5. Cheng H, Geist DE, Piperdi M, Virk R, Piperdi B (2009) Management of imatinib-related exacerbation of psoriasis in a patient with a gastrointestinal stromal tumor. *Australas J Dermatol* 50: 41-43.
6. Valeyrie L, Bastuji-Garin S, Revuz J, Bachot N, Wechsler J, et al. (2003) Adverse cutaneous reactions to imatinib (STI571) in Philadelphia chromosome positive leukemias: a prospective study of 54 patients. *J Am Acad Dermatol* 48: 201-206.
7. Nagai T, Karakawa M, Komine M, Muroi K, Ohtsuki M, et al. (2013) Development of psoriasis in a patient with chronic myelogenous leukaemia during nilotinib treatment. *Eur J Hematol* 91: 270-272.
8. Kaur S, Arora AK, Sekhon JS, Sood N (2015) Nilotinib-induced psoriasis in a patient of chronic myeloid leukemia responding to methotrexate. *Indian J Dermatol Venereol Leprol* 81: 216-218.
9. Mattozzi C, Salvi M, D'Epiro S, Giancristoforos S, Macaluso L, et al. (2013) Importance of regulatory T cells in the pathogenesis of psoriasis: Review of literature. *Dermatology* 227: 134-145.
10. Chen J, Schmitt A, Giannopoulos K, Chen B, Rojewski M, et al. (2007) Imatinib impairs the proliferation and function of CD4+ CD25+ regulatory T cells in a dose dependent manner. *Int J Oncol* 31: 1133-1139.
11. Chen J, Scmitt A, Chen B, Rojewski MT, Rubeler Y, et al. (2008) Nilotinib hampers the proliferation and function of CD8+T lymphocytes through inhibition of T cell receptor signaling. *J Cell Mol Med* 12: 2107-2118.
12. Fei F, Yu Y, Schmitt A, Rojewski MT, Chen B, et al. (2010) Effects of nilotinib on regulatory T cells: The dose matters. *Mol Cancer* 9: 22.
13. Miyagawa S, Fujimoto H, Ko S, Hirota S, Kitamura Y (2002) Improvement of psoriasis during imatinib therapy in a patient with a metastatic gastrointestinal stromal tumor. *Br J Dermatol* 147: 406-407.
14. Fei F, Yu Y, Schmitt A, Rojewski MT, Chen B, et al. (2009) Dasatinib inhibits the proliferation and function of CD4 + CD25 + regulatory T cells. *Br J Haematol* 144: 195-205.