

Acute Acalculous Cholecystitis following The Cemented Hemiarthroplasty in an Elderly Hip Fracture Patient: Case Report

Bin Zhao*

Department of Orthopedics, Second Hospital of Shanxi Medical University, 382 Wuyi Road, Taiyuan, Shanxi, PRC 030001, China

*Corresponding Author: Bin Zhao, Department of Orthopedics, Second Hospital of Shanxi Medical University, 382 Wuyi Road, Taiyuan, Shanxi, PRC 030001, China, Tel: 0351-3366120; E-mail: zhaobinmd@163.com

Received date: June 8, 2017; Accepted date: June 12, 2017; Published date: June 23, 2017

Copyright: © 2017 Zhao B. This is an open-access article distributed under the terms of the Creative Commons Attribution License, which permits unrestricted use, distribution, and reproduction in any medium, provided the original author and source are credited.

Abstract

Postoperative acute acalculous cholecystitis (AAC) was a well-known abdominal complication of general surgery [1-3], but in orthopedic surgery only sporadic case reports could be retrieved [4-7]. Postoperative AAC was unrelated to the biliary tract, which was characterized by gallbladder inflammation without evidence of calculi or sludge [8]. Once postoperative AAC occurs, the disease progressed fastly, such as obscure, fulminating, and rapid progression to sepsis and perforation, which may eventually lead to death. As far as we know, there has been no report published about AAC following cemented hemiarthroplasty in hip fracture patients. Herein, we report an extremely rare case of postoperative AAC following cemented hemiarthroplasty in a hip fracture patient where proper diagnosis was made and an otherwise potentially fatal outcome was averted.

Introduction

Postoperative acute cholecystitis is a well-known complication especially when the abdominal area is involved. Orthopaedic surgeries not related to the abdominal area, however, are also associated with this complication. Duncan first reported acute cholecystitis as a postoperative complication after a femoral hernia repair procedure in 1844. Fisher described a case of acute cholecystitis following an open reduction of the scaphoid bone for a 19-year old football player in 1933 [9]. By 1960s, over a hundred cases of postoperative acute cholecystitis had been reported that were unrelated to abdominal procedures, including dozens of orthopaedic procedures [10-13]. The review by Abrahamson et al in 1988 had shown orthopaedic operation to be the second most common reason for acute cholecystitis, accounting for 16.5%.

Hip procedures, however, are far less likely to induce acute cholecystitis. According to Deleanu et al, out of 1499 patients who underwent hip surgeries, there were 7 cases of abdominal complications and one of which were acute cholecystitis. Choo et al. reported 9 instances of postoperative acute cholecystitis out of 1211 elderly hip fracture patients, or 0.74% [14].

Although its occurrence is rare, it has a high risk of leading to fatal outcomes if overlooked or misdiagnosed. Here we report a lone case of acute acalculous cholecystitis (AAC) out of a total of 469 cases of elderly patients who underwent orthopedics surgeries at our hospital for their hip fractures in the 3-year period of January 2012 to January 2015.

Case Report

A 76-year-old female had slipped and fallen in a sitting position in the bathroom of her house. She was admitted to the hospital approximately seven hours after the fall and was subsequently diagnosed to have a closed fracture of the left femoral neck. She underwent cemented hemiarthroplasty (Figure 1) surgery under general anesthesia five days later. During the operation, and upon completion of bone cementing, her systolic pressure suddenly dropped from 110 mmHg to 80 mmHg before returning to 110 mmHg a minute later. She was then transferred back to the ward after the completion of surgery.

The morning after the day of surgery, the patient reported a chilling sensation and intermittent sweating with a fever up to 39. Upon physical examination, there was neither tenderness nor heating on the site of operation. However, there was right abdominal tenderness with as positive Murphy's sign. Emergency laboratory results were as follows: white blood cell count, $14.57 \times 10^9/L$; erythrocyte sedimentation rate, 85 mm/h; C-reactive protein, 45.30 g/L; total bilirubin, 4.4 mg/dL. Other blood biochemistry tests were normal. Physical examination later in the evening revealed that the patient had a pain in the right upper quadrant with a positive Murphy's sign. Abdominal CT scan and ultrasound showed acute cholecystitis and multiple liver microabscesses (Figure 2).

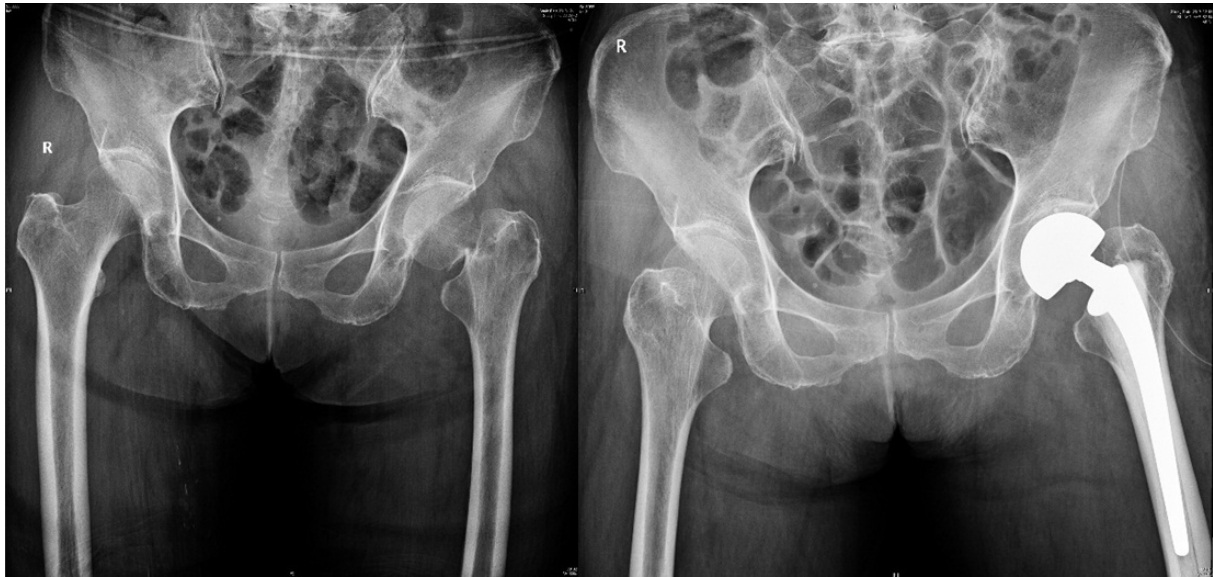

Figure 1: Preoperative X-ray showed left displaced femoral fracture, postoperative X-ray showed the bone cement prostheses.

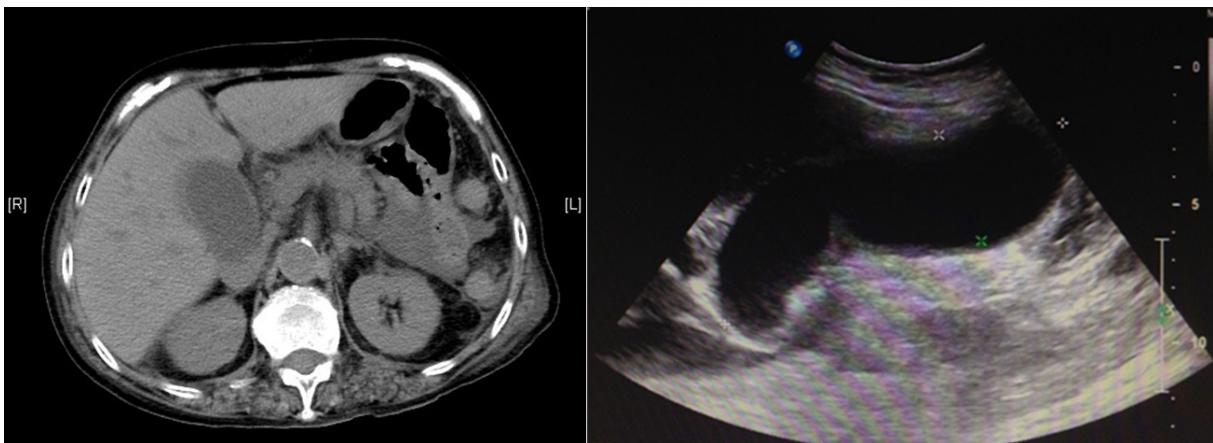


Figure 2. Abdominal CT scan and ultrasound showing cholecystitis.

Emergency percutaneous transhepatic gallbladder drainage (PTGBD) was carried out, and the patient was treated with analgesics and antibiotics. The acute state gradually subsided over a period of 3 weeks and a laparoscopic cholecystectomy was performed, after which the patient was discharged without further complications.

Discussion

There are many factors which may induce AAC, including stasis of highly viscid bile which is induced by hypervolemia, fever shock, dehydration and obstruction at the sphincter of Oddi which can be induced by starvation, narcotics and anesthesia. However, orthopedic surgeons must pay attention to one special condition – bone cement implantation syndrome (BCIS). In a case reported in 2012 [15], a 70-year-old patient who underwent kyphoplasty under conscious sedation for compression fracture of the T12 developed acute cholecystitis.

Although the author attributed it to gallstone, BCIS may have played an important role in that case.

Bone cement implantation syndrome (BCIS) is a common and fatal complication in orthopedic procedures [16]. It occurs mostly in cement hip replacements. The reason for BCIS is not yet fully understood. The main explanations include the release of cement methyl methacrylate (MMA) monomers into the circulation, emboli formation during cementing and prosthesis insertion [17], histamine release [18] and complement activation [19]. Firstly, BCIS is mainly concerned with the impact on circulation and the respiratory system [20]. In our department, we have approximately 50 patients undergoing hip arthroplasty for elderly femoral neck fracture patients each year. We have recorded the blood pressure change for all patients during their operations. The results showed transient hypotension occurring in almost half the patients, including the present case in discussion.

However, BCIS may not only affect the circulation and the respiratory system but also damage other organs such as the liver, the kidney and the pancreas. In a case report by Razuin et al [21], a 59-year-old female who underwent total hip replacement had died of BCIS. Autopsy showed an inflamed and haemorrhagic pancreas and histopathology showed the existence of fat and marrow elements in the blood vessels of the liver and the kidneys. The pancreas showed acute inflammatory cell infiltrates, patchy areas of haemorrhage and necrosis and also surrounding fat necrosis. In our case, we have concluded that BCIS played an important role. The emboli may have affected the blood supply of gallbladder or the toxicity of the MMA may have caused it.

In conclusion, even if an operation is not related to the abdomen, physicians should pay attention to the potential of postoperative acute acalculous cholecystitis, especially for orthopedic procedures involving bone cement.

References

1. Thompson JW, Ferris DO, Baggenstoss AH (1962) Acute cholecystitis complicating operation for other diseases. *Ann Surg* 155: 489-494.
2. Ottinger LW (1976) Acute cholecystitis as a postoperative complication. *Ann Surg* 184: 162-165.
3. Abrahamson J, Eldar S (1988) Acute cholecystitis after orthopedic operations. *Int Orthop* 12: 93-95.
4. Duncan J (1844) Femoral hernia; gangrene of gallbladder; extravasation of bile; peritonitis; death. *North J Med* 2:151-153.
5. Deleanu B, Prejbeanu R, Vermesan D, Haragus H, Icma I, et al. (2014) Acute abdominal complications following hip surgery. *Chirurgia (Bucur)* 109: 218-222.
6. Abrahamson J, Eldar S (1988) Acute cholecystitis after orthopaedic operations. *Int Orthop* 12: 93-95.
7. Floman Y, Micheli LJ, Barker WD, Hall JE (1980) Acute cholecystitis following the surgical treatment of spinal deformities in the adult: a report of three cases. *Clin Orthop Relat Res* 151: 205-209.
8. Gomez-Pinilla PJ, Camello PJ, Tresguerres JA, Pozo MJ (2010) Tempol protects the gallbladder against ischemia/reperfusion. *J Physiol Biochem* 66: 161-172.
9. Vest SA Jr (1933) Gangrene of the gallbladder. *Internat Surg Digest* 15: 131-160.
10. Glenn F (1947) Acute Cholecystitis Following the Surgical Treatment of Unrelated Disease. *Ann Surg* 126: 411-420.
11. Schwegman CW, De Muth WE Jr (1953) Acute cholecystitis following operation for unrelated disease. *Surg Gynecol Obstet* 97: 167-172.
12. Sparkman RS (1952) Abdominal emergencies following unrelated surgical procedures. *Ann Surg* 135: 863-874.
13. Thompson JW, Ferris DO, Baggenstoss AH (1962) Acute cholecystitis complicating operation for other diseases. *Ann Surg* 155: 489-494.
14. Choo SK, Park HJ, Oh HK, Kang YK, Kim Y (2015) Acute cholecystitis in elderly patients after hip fracture: Incidence and epidemiology. *Geriatr Gerontol Int Wiley-Blackwell* 16: 380-383.
15. An SB, Yim J, Kim E, Shin JH, Park SY, et al. (2012) Acute cholecystitis developed immediately after thoracic kyphoplasty-A case report. *Korean J Anesthesiol* 63: 266-269.
16. Kalra A, Sharma A, Palaniswamy C, S El-Oshar, Desai P, et al. (2013) Diagnosis and Management of Bone Cement Implantation Syndrome: Case Report and Brief review. *Am J Ther* 20: 121-125.
17. Donaldson AJ, Thomson HE, Harper NJ, Kenny NW (2009) Bone cement implantation syndrome. *Br J Anaesth* 102: 12-22.
18. Tryba M, Linde I, Voshage G, Zenz M (1991) Histamine release and cardiovascular reactions to implantation of bone cement during total hip replacement. *Anaesthetist* 40: 25-32.
19. Lewis RN (1997) Some studies of the complement system during total hip replacement using bone cement under general anaesthesia. *Eur J Anaesth* 14: 35-39.
20. Kotyra M, Houltz E, Ricksten SE (2010) Pulmonary haemodynamics and right ventricular function during cemented hemiarthroplasty for femoral neck fracture. *Acta Anaesthesiol Scand* 54: 1210-1216.
21. Razuin R, Effat O, Shahidan MN (2013) Bone cement implantation syndrome. *Malaysian J Pathol* 35: 87-90.